

RESENTING CLINICAL SIGNS

DATE History: New murmur. Radiographs show mild cardiomegaly.

ECHOCARDIOGRAPHIC FINDINGS

10/7/21 2D, M-mode, and Doppler study.

PERFORMED BY:

Dr. Meredith Swart

There is mild left atrial dilation. The mitral valve leaflets are thickened and exhibit systolic prolapse. A mild to moderate jet of mitral regurgitation is present. There is mild left ventricular dilation. Left ventricular systolic function is hyperdynamic. The aorta and aortic valve are normal. Right atrial and right ventricular dimensions are normal. The tricuspid valve is normal. The pulmonary artery and pulmonic valve appear normal, though trace pulmonic insufficiency is present. No pericardial effusion or cardiac masses are seen.

INTERPRETED BY

Keith Blass, DVM,
MS, DACVIM
(Cardiology)

LA - 31.9 mm
LVIDd - 32.1 mm
LVIDs - 16.3 mm
FS - 49%
LVOT - 1.36 m/s
RVOT - 0.89 m/s

PATIENT

Tinkerbelle Coelho

ASSESSMENT/RECOMMENDATIONS

Degenerative mitral valve disease

SPECIES

Canine

This examination demonstrates mild to moderate regurgitation of blood across Tinkerbelle's mitral valve resulting from degenerative valve disease. Secondary to her regurgitation, Tinkerbelle has mild dilation of both her left atrium and left ventricle, though her left ventricular systolic function is well-preserved. As only mild left heart chamber dilation is present, Tinkerbelle's mitral valve disease appears to be well-compensated, though careful monitoring for the development of clinical signs, such as coughing, exercise intolerance, syncope, and labored breathing, is recommended going forward.

BREED

Terrier Mix

I recommend starting Tinkerbelle on pimobendan (2.5 mg am, 1.25 mg pm), as this medication should help to slow the progression of her mitral valve disease.

SEX

FS

A recheck (X-ray +/- echocardiogram) is recommended in 6-9 months, sooner if new clinical signs compatible with cardiac dysfunction develop.

AGE

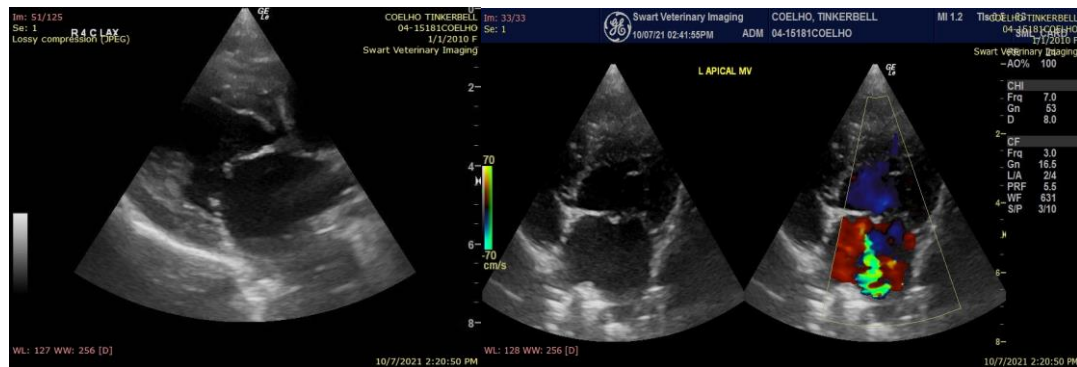
11 y

WEIGHT

15.4 lb

HOSPITAL NAME

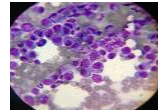
Swart Veterinary
Imaging



REFERRING VET

Dr. Swart

The information and recommendations provided are based on the images presented by the referring veterinarian. No evaluation can be communicated regarding pathology that was not



visible in the image/video clips provided.

DATE

10/7/21

Thank you for this referral. If the clinical or image interpretation does not parallel your findings or if I can be of any further assistance please contact me.

PERFORMED BY:

Keith Blass, DVM, MS, DACVIM (Cardiology)
KeithBlass@gmail.com
631-804-5754

Dr. Meredith Swart

INTERPRETED BY

Keith Blass, DVM,
MS, DACVIM
(Cardiology)

PATIENT

Tinkerbelle Coelho

SPECIES

Canine

BREED

Terrier Mix

SEX

FS

AGE

11 y

WEIGHT

15.4 lb

HOSPITAL NAME

Swart Veterinary
Imaging

REFERRING VET

Dr. Swart